

Diagnose Glaucoma by Proposed Image Processing Methods

Dnyaneshwari D.Patil
M. Phil.(Research student)
Dept of CS and IT,
Dr. B. A. M.
University,
Aurangabad (MS)
(India)

RameshManza, Ph.D.
Assistant professor
Dept of CS and IT,
Dr. B. A. M.
University,
Aurangabad (MS)
(India)

Gangadevi C. Bedke
M. Phil. (Research student)
Dept of CS and IT,
Dr. B. A. M.
University,
Aurangabad (MS)
(India)

ABSTRACT:

Glaucoma is one of the leading cause of blindness worldwide. It is due to the increase in intra ocular pressure within the eyes. The detection and diagnosis of glaucoma is very important. There are manual and automatic detection methods available. In this paper a survey is conducted on different glaucoma detection methods such as Scanning Laser Polarimetry, optical coherence tomography, including- image processing in Enhancement, Registration, Fusion, Segmentation, Feature extraction, Pattern matching, Classification, Morphology, Statistical measurements and Analysis etc

Keywords:

Glaucoma, Cup to disc ratio, Segmentation, Neural network for classification

1. INTRODUCTION

Glaucoma is one of the many eye diseases can lead to the blindness if it is not detected and treated in proper time. It is often associated with the increased in the intraocular pressure (IOP) of the fluid (known as aqueous humour) in eye, and it has been nicknamed as the “Silent Thief of Sight”.

Glaucoma is the second leading cause of blindness in the world. It affects 40% of Blindness in Singapore, more than 3 million peoples living in the United States. Glaucoma is the leading cause of blindness in African – Americans, who should begin glaucoma tests as early as age 35.

Before touch the objective we see the fig1.**An anatomy of human eye** approximately a spherical organ shown in above fig. The protective outer layer of the eye is called the sclera. The other components of the eye are regions such as cornea, lens, iris, and retina. Retina is approximately 0.5-mm thick and covers the inner side at the back of the eye. The center of the retina is the optical disc, a circular to oval white area measuring about 3 mm² (about 1/30of retina area). The mean diameter of the vessels is about 250µm.

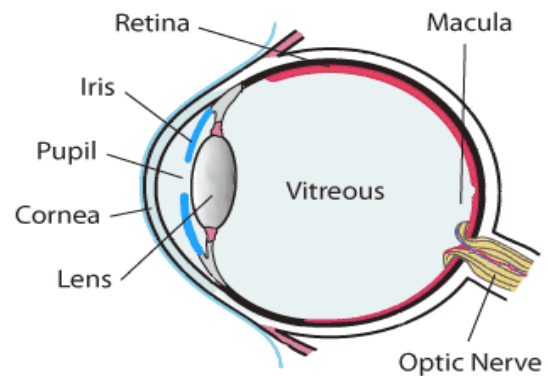


Figure 1 Anatomy of human Eye:

The medical diagram of normal eye and glaucoma affected eye with optic nerve damage due to intraocular pressure is shown in following fig 2.

The early stages of glaucoma will damage the optic nerve without incurring any symptom. The patients are not aware of the disease until the advanced stage of disease occurs which makes total blindness.

The damage caused is irreversible, but treatment can prevent progression of the disease if detected in the early stage. Thus, the early detection of glaucoma has been essential and compulsory.

Clinically, the diagnosis of Glaucoma can be done through measurement of CDR, defined as the ratio of the vertical height of the optic cup to the vertical height of the optic disc. An increment in the cupping of Optic Nerve Head (ONH) corresponds to the increased ganglion cell death and hence CDR can be used to measure the probability of developing the disease. A CDR value that is greater than 0.65 indicates the high glaucoma risk [3].

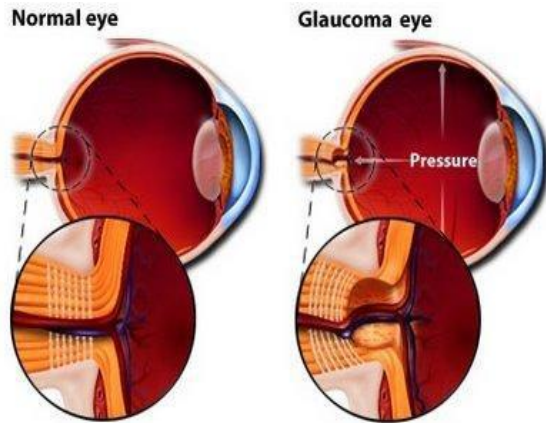


Figure 2 Medical image of normal and affected eye.

2. DISCUSSION:

2.1 Types of Glaucoma:

2.1.1 Primary Open Angle Glaucoma:-

This type of glaucoma is the most common (sometimes called as Chronic Glaucoma) and symptoms are slow to develop. As the glaucoma progresses the side or peripheral vision is failing. It may cause a person to miss the objects out of the side or corner of the eye. It happens when the eye's drainage canals become clogged over time or the eye over-produces aqueous fluid which causes the pressure inside the eye to build to abnormal levels. The inner eye pressure (IOP) rises because the correct amount of fluid can't drain out of the eye. It's affecting 70% to 80% of those who suffered from the disorder and accounts for 90% of glaucoma cases in the United States. It is painless and does not have acute attacks. It can develop gradually and go unnoticed, especially if caught early and treated.[5]

2.1.2 Angle Closure Glaucoma:-

Also known as Acute Narrow Angle Glaucoma and accounts for less than 10% of glaucoma cases in the United States. Although it is rare and different from open angle glaucoma, it is the most serious form of disease. The problem occurs more commonly in farsighted elderly people, particularly in women and often occurs in both eyes. Angle Closure Glaucoma occurs primarily in patients who have shallow space between the cornea at the front of the eye and the colour iris that lies just behind the cornea. As the eye ages, the pupil grows and becomes smaller, restricting the flow of fluid to the drainage site. As fluid builds up and blockage happens, a rapid rise in intraocular pressure can occur [7].

This kind of Glaucoma is normally very painful because of the sudden increase in pressure inside in the eye. The symptoms of an acute attack are more severe and can be totally disabling. They include severe pain, often accompanied by nausea and vomiting. Diabetes can be a contributing cause to the development of glaucoma. Treatment of angle closure glaucoma is known as peripheral iridectomy and usually involves surgery to remove a small portion of the outer edge of the iris to allow aqueous fluid to flow easily to the drainage site. [6]

2.1.3 Secondary Glaucoma

Both open angle glaucoma and angle closure glaucoma can be primary or secondary conditions. Primary conditions are when the cause is unknown, unlike secondary conditions which can be traced to a known cause. Secondary glaucoma may be caused by a variety of medical conditions, medications, eye abnormalities and physical injuries. The treatment of secondary glaucoma is frequently associated to eye surgery.

2.2 Glaucoma Diagnosis Techniques

There are multiple tests available for detection of glaucoma but in this research work I will use ophthalmoscope for the detection of glaucoma.

2.2.1 Ophthalmoscopy:

This diagnostic procedure helps the doctor examine your optic nerve for glaucoma

damage. Eye drops are used to dilate the pupil so that the doctor can see through your eye to examine the shape and colour of the optic nerve.

The doctor will then use a small device with a light on the end to light and magnify the optic nerve. If your intraocular pressure is not within the normal range or if the optic nerve looks unusual, your doctor may ask you to have one or two more glaucoma exams: perimetry and gonioscopy. Doing this test increased intraocular pressure and damage the optic nerve and to measure this damage the ophthalmoscopy test are used. To detect the ophthalmoscopy test doctor uses the instruments to look back of the eye.

2.2.2 Slit-Lamp Microscopy

Slit-lamp microscopy is of fundamental importance in the treatment of glaucoma. In this examination, the conjunctivae, anterior chamber, eye iris, lens, etc., are observed, but an auxiliary lens may also be used in combination in order to observe the anterior chamber angle and ocular fundus.

2.3 Gonioscopy

Gonioscopy is indispensable in the treatment and diagnosis of glaucoma. In gonioscopy, it is important to properly recognize the various structures composing the anterior chamber angle, such as Schwalbe's line, the trabecular meshwork, the scleral spur, and the ciliary band.

2.3.1 Schwalbe's line

Schwalbe's line is located in an area equivalent to the ending portion of the Descemet membrane

and extends into the anterior chamber.

2.3.2 Trabecular meshwork

The trabecular meshwork and Schlemm's canal are located between Schwalbe's line and the scleral spur. From the center of the trabecular meshwork, the scleral spur side is equivalent to the functional trabecular meshwork and is observed as a pigment band.

2.3.3 Scleral spur

The scleral spur is observed as a white line between the ciliary band and the trabecular meshwork. Iridial protrusions are frequently seen on the surface thereof. In eyes with developmental glaucoma, the iris shows synechiae anterior to the scleral spur, and the scleral spur cannot be observed.

2.3.4 Ciliary band

The ciliary band is equivalent to the anterior surface of the ciliary body, and it is observed as a grayish-black band.

2.4 TONOMETRY

2.4.1 Intraocular pressure

Results of studies conducted in large numbers of subjects have shown that the distribution of IOP is skewed towards higher values and does not show a fully normal distribution.

2.4.2 Tonometers

As the Goldmann applanation tonometer is the most clinically accurate device, this tonometer is used on a standard basis in the diagnosis and treatment of glaucoma. The Goldmann applanation tonometer, unlike applanation tonometers such as the Schiötz tonometer, has the advantage that measurement values are not affected by ocular wall hardness. The Tono-Pen and the Perkins applanation tonometer are portable tonometers in which IOP measurements can be conducted with the patient seated or supine.

2.5 Perimetry:

The normal visual field has an elongated elliptical shape, and with respect to the fixation point, it measures 60 degrees superiorly and medially, 70-75 degrees inferiorly, and 100-110 degrees temporally. The two means for measuring the visual field are dynamic and static measurement. Perimeters express the brightness of the target in units of apostilbs (asb). 1 asb is equivalent to 0.3183 candela/m². [8]

3. PROPOSED METHOD:

Image processing technique:

Various image processing techniques used in automated early diagnosis and analysis of various eye disease are Enhancement, Registration, Fusion, Segmentation, Feature extraction, Pattern matching, Classification, Morphology, Statistical measurements and Analysis.

Image Enhancement- Image enhancement includes varying brightness and contrast of image. It also includes filtering and histogram equalization. It comes under pre-processing step to enhance various features of image.

Image Registration- Image Registration is an important technique for change detection in retinal image diagnosis. In this process, two images are aligned onto a common coordinate system. Images may be taken at different times and with imaging devices. In medical diagnosis, it is essential to combine data from different images and for better analysis and measurements images are aligned geometrically.

Image Fusion- Image fusion is a process of combining information acquired from number of imaging devices. Its goal is to integrate contemporary, multi sensor, multi-temporal or multi-view information into a single image, containing all the information so as to reduce the amount of information.

3.1 Segmentation, Morphology for Feature Extraction:

Feature Extraction- It is the process of identifying and extracting region of interest from the image.

Segmentation- Segmentation is the process of dividing an image into its constituent object and group of pixels which are homogenous according to some criteria. Segmentation algorithms are area-oriented instead of pixel oriented. The main objective of image segmentation is to extract various features of image which can be merged or split in order to build object of interest on which analysis and interpretation can be performed. It includes clustering, thresholding etc.

Morphology- Morphology is the science of appearance, shape and organization. Mathematical morphology is a collection of non-linear processes which can be applied to an image to remove details smaller than a certain reference shape. Various morphological operation are erosion, dilation, opening and closing.

CDR(Cup to disc ratio)- The vertical cup-to-disc ratio (CDR) is one of the most important risk factors in the diagnosis of glaucoma [9]. It is defined as the ratio of the vertical cup diameter over the vertical disc diameter. The optic disc is the location where the optic nerve connects to the retina. In a typical 2D fundus image, the optic disc is an elliptic region which is brighter than its surroundings. The disc has a deep excavation in the center called the optic cup. It is a cup-like area devoid of neural retinal tissues and normally white in color, OC of a glaucomatous eye tends to grow over time due to persistently increased intraocular pressure. As the OC grows, the neuroretinal rim located between the edge of the OD and the OC which contains optic nerve fibers becomes smaller in area. If the neuroretinal rim is too thin, vision will be deteriorated. Thus, quantitative analysis of the optic disc cupping can be used to evaluate the progression of glaucoma [10]. As more and more optic nerve fibers die, the OC becomes larger with respect to the OD, which corresponds to an increased CDR value. For a normal subject, the CDR value is typically around 0.2 to 0.3. Typically, subjects with CDR value greater than 0.6 or 0.7 are suspected of having glaucoma and further testing is often needed to make the diagnosis [11].

3.2 Neural Network for Classification

The Probabilistic Neural Network was developed by Donald Speech. Classification refers to the analysis of the properties of an image. Depending upon the analysis, the dataset is further referred into different classes. Input features are categorized as 0 and 1. The classification process is divided into two phases: training phase and testing phase [13]. In the training phase, known data is given and in the testing phase, an unknown data is given. Classification is done by using classifier after the training phase [12]. The Probabilistic Neural Network provides a general solution to pattern classification problems [14].

3. Classification- Classification is an important technique of image analysis for estimation of statistical parameter according to the gray level intensities of pixels. It includes labelling of a pixel or group of pixels based on the grey values and other statistical parameters. For understanding the contents of an image, image analysis functions are used [4]. The proposed method focuses on optic disk and cup segmentation.

4. GLAUCOMA DETECTION FLOW-DIAGRAM

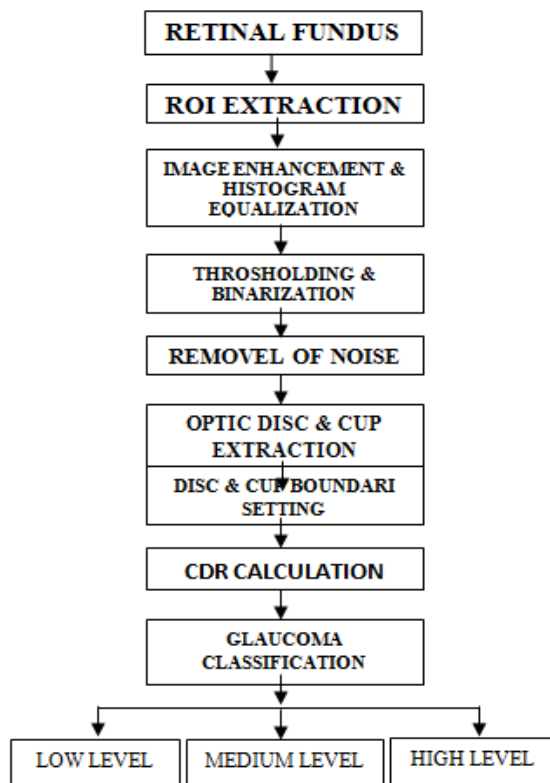


Figure 3: Simplified work flow of computer aided glaucoma diagnosis through image processing methods [3]

5. CONCLUSION

In this paper it is concluded that for detection and diagnosis of glaucoma, there are multiple medical tests are available ,but on behalf of some tests image processing techniques are applied on the retinal fundus images and getting more accurate result though it.In future we will deeply work on Glaucoma detection technique using various image processing methods.

6. REFERENCES

[1] Dharmanna Lamani- (IJTR) "Bidirectional fractal dimension through semi variance applied to glaucomatous eye" Volume No. 1, Issue No. 6, October - November 2013, 562 - 566.
[2] Preeti1, Jyotika Pruthi, "Review of Image Processing Technique for Glaucoma Detection"

[3] IJCSMC, Vol. 2, Issue. 11, November 2013, pg.99 – 105. 1A. Murthi and 2M.Madheswaran-
[4] "Estimation of Cup to Disc Ratio to Improve the Glaucoma Diagnosis for Health" Care Systems Australian Journal of Basic and Applied Sciences ISSN:1991-8178
[5] Review of Image Processing Technique for Glaucoma Detection *IJCSMC, Vol. 2, Issue. 11, November 2013, pg.99*
[6] http://www.youtube.com/watch?v=eLrF8Klos5M&feature=youtube_gdata_player
[7] http://www.youtube.com/watch?v=IPqB0hHczJ4&feature=youtube_gdata_player
[8] https://www.google.co.in/search?q=glaucoma+image&source=1nms&tbm=isch&sa=X&ei=ok5fU4eFDca hugS36IGYDg&sqi=2&ved=0CAYQ_AUoAQ&biw=1366&bih=66
[9] Japan Glaucoma Society Guidelines for Glaucoma (2nd Edition)
[10] ACHIKO-I Retinal Fundus Image Database and its Evaluation on Cup-to-Disc Ratio Measurement Fengshou Yin, Jiang Liu, Damon Wing Kee Wong, Ngan Meng Tan, Beng Hai Lee, Jun Cheng, Min The Htoo, Zhuo Zhang, Yanwu Xu and Xinting Gao
[11] J.B. Jonas, W.M. Budde and S. Panda-Jonas, "Ophthalmoscopic evaluation of the optic nerve head," *Surv Ophthalmol*, vol. 43, no. 4, pp. 293-320, Jan-Feb 1999.
[12] Y.H. Kwon, J.H. Fingert and E.C. Greenlee, *A Patient's Guide to Glaucoma* FEP International, 2008.
[13] M.Vinay Kumar, SharadKulkarini, "Tumors Classification using PNN Methods", Volume-2, Issue-5, International Journal of Soft Computing and Engineering (IJSCE), November 2012.
[14] Ali Asghar Beheshti Shirazi, Leila Nasser, "Novel Algorithm to Classify Iris Image Based on Entropy by Using Neural Network", International Conference on Advanced Computer Theory and Engineering, IEEE 2008.
[15] N.Annu1, Judith Justin2, 2Faculty, Dept of Biomedical Instrumentation Engg, Avinashilingam University, Coimbatore, India Email: judithvjn@yahoo.co.in "Automated Classification of Glaucoma Images by Wavelet Energy Features."