

# **Study of Macular Degeneration with Respect to Artifacts on Retinal Images**

**Srikanth Prabhu**  
Department of Computer Science & Engineering,  
MIT Manipal University, Manipal  
India-576104

**Chandan Chakraborty**  
Asst. Professor, School of Medical Science &  
Technology IIT Kharagpur

**R.N. Banerjee**  
Professor, Dept. of IEM, IIT Kharagpur

**A. K. Ray**  
Professor, Dept. of E&EC, IIT Kharagpur

## **ABSTRACT**

The role of segmentation in image processing is to separate foreground from background. In this process, the features become clearly visible when appropriate filters are applied on the image. In this paper emphasis has been laid on segmentation of biometric retinal images to filter out the vessels explicitly for evaluating the bifurcation points and features for diabetic retinopathy. Segmentation on images is performed by calculating ridges or morphology. Ridges are those areas in the images where there is sharp contrast in features. Morphology targets the features using structuring elements. Structuring elements are of different shapes like disk, line which is used for extracting features of those shapes. When segmentation was performed on retinal images problems were encountered during image pre processing stage. Also edge detection techniques have been deployed to find out the contours of the retinal images. After the segmentation has been performed, it has been seen that artifacts of the retinal images have been minimal when ridge based segmentation technique was deployed. In the field of Health Care Management, image segmentation has an important role to play as it determines whether a person is normal or having any disease specially diabetes. In India alone more than 5 million people are affected by diabetes. During the process of segmentation, diseased features are classified as diseased one's or artifacts. The problem comes when artifacts are classified as diseased one's. This results in misclassification which has been discussed in the analysis section. Macular Degeneration is one of the diseases in diabetic retinopathy which will never be classified as artifacts due to the size of exudates. In this paper an attempt has been made to evaluate macular degeneration.

**Keywords** : Pupil, Sclera, Limbus, Diabetes, Micro-aneurysms, Exudates, Gabor, LoG, Bifurcation, Sobel, Gray level, Decision tree, KNN.

**General Terms:** Peripheral for boundaries, G for gaussian, N for normalization.

## **1. INTRODUCTION**

The human eye is made up of sclera, limbus, pupil and retina. Sclera is the white portion of the iris. Sclera surrounds the pupil. The retina is made up of optical ball, fovea and the vessels. The vessels give lot of information like the bifurcation points, optical ball, fovea. The fovea is the illumination region of retina. The bifurcation points branch the vessels into finer pieces. In this paper an innovative method to extract the vessels with macular degeneration has been proposed using the ridge based segmentation technique. Ridge based segmentation technique works well with biometrics where the color information is of lesser intensity. For example with faces for generating templates of the same individual, ridge based segmentation gives good results. Over the years it has been seen that biometric information fails to capture details of people who replicate themselves using some or the other medical techniques. These biometric information are related to fingerprints, faces, handwriting. But if retina is considered, then the information gathered about any individual is unique because retinal data cannot be duplicated from one person to another person. Therefore if retina is considered to be a superior biometric then segmentation of the images have to be done, keeping in mind the artifacts of the images. Artifacts are distortions in the images. These distortions look to be features which contribute to classification but they don't contribute to the anatomy and physiology of retina. Researches in the modern times have gone for morphology as a replacement tool for segmentation. In this paper a step by step procedure has been shown for segmentation of retinal images. Section 2 deals with Laplacian of Gaussian filter to detect the blood vessels. Section 3 deals with detection of bifurcation points using Laplacian of Gaussian filter. Section 4 deals with detection of blood vessels using morphology. Section 5 deals with detection of bifurcation points using gabor filter. Section 6 deals with segmentation of vessels using ridge based segmentation technique.

## **2. DETECTION OF BLOOD VESSELS USING LAPLACIAN OF GAUSSIAN FILTER**

The vessels are extracted using local maxima and local minima[11]. For example the local maxima for 16 16 17 is 16 17 17. The LoG[19] function looks as follows:

$$g(x, y, t) = \frac{1}{2\pi t^2} e^{-\frac{(x^2 + y^2)}{2t^2}}$$

Eq-1.

$$\Rightarrow L(x, y, t) = g(x, y, t) * f(x, y)$$

Eq-2.

$$\Rightarrow \text{Laplacian Operator} = \nabla^2 L = L_{xx} + L_{yy}$$

Eq-3.

Where  $f(x, y)$  is the image.

The results are shown in Fig 1.

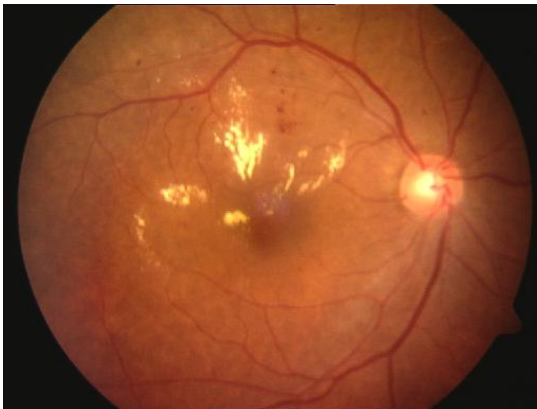


Fig 1 (a): Shows retina with macular degeneration.

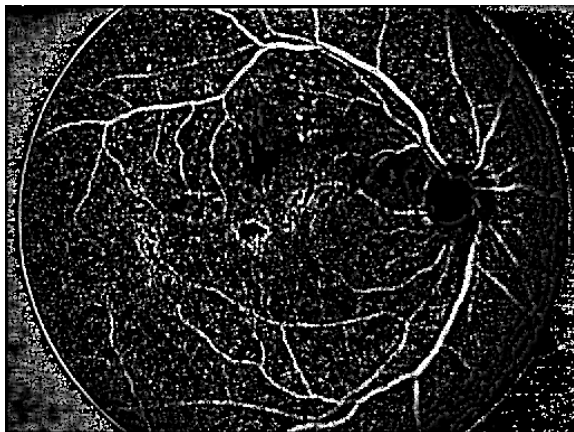


Fig 1 (b): Shows the effect of LOG on a retinal image.

### 3. DETECTION OF BIFURCATION POINTS USING LAPLACIAN OF GAUSSIAN FILTER

Here first the R, G, B[2, 3] components are extracted from the

image. After performing the histogram equalization, Laplacian of Gaussian filter is applied on the image. A structuring element disk of size 1 is applied and subsequently the image is eroded and dilated. The structuring element is so chosen that 'Y'[7] shapes are got from the retinal images. Then the maximum and minimum of pixel intensities are evaluated and these values are subtracted to get the subsequent edges. Then using two straight lines as structuring elements, noise is removed. Then using the Painter's algorithm[13,14] where in we take the binary format of the image, and where ever we have higher values of pixels for the binary image(white), we replace them with low values of pixels (black). Thus superimposition of bifurcation points is obtained over the original image. The steps for evaluating the bifurcation points are given as follows:

- a) Get R, G, B component of the images.
- b) Perform Histogram Equalization[11] of the image.
- c) Apply Laplacian of Gaussian on the pre processed image.
- d) Take a structuring element disk of size 1 and erode and dilate (Morphological opening) the image.
- e) Find difference of Maximum and Minimum[11]of each pixel.
- f) Find edges using Sobel Filter[11].
- g) Use Structuring elements which are two lines to remove the noise.
- h) Find negation of the image.

The results are shown in Fig 2.




Fig 2 (a): Shows salt and pepper noise

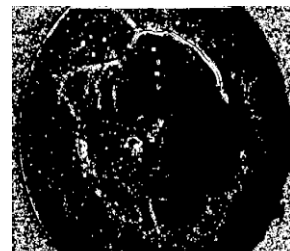

Fig 2 (b): Shows salt and pepper noise in black background.



Fig 2 (c): Shows Bifurcation points.



Fig 2 (d): Shows extraction of Bifurcation points using LOG filter.

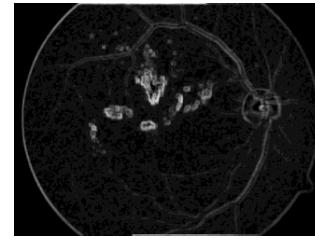


Fig 3 (c) Shows Exudates ( With Blur).

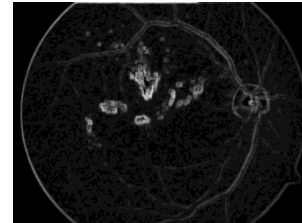


Fig 3 (d): Shows Exudates ( Smoothened).

#### 4. DETECTION OF BLOOD VESSELS USING MORPHOLOGY

Here we first apply a structuring element disk of size 40 to avoid artifacts and then subsequently dilation and erosion of the image is performed. The residue[12] is calculated as the subtraction of dilated[14] minus the eroded image. The areas where the residue is less than five, we display the image. The steps for morphology are given below:

- Use a structuring element[15] square of size 40.
- Dilate and Erode[16] the image using the structuring element.
- Calculate Residue as (Dilated – Eroded) image.
- For all the pixels which have residue less than ten, display the image.

The results are shown in Fig 3.

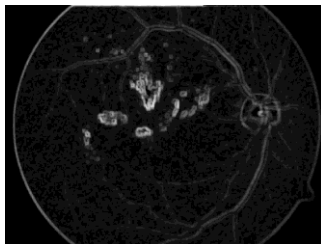


Fig 3 (a): Shows Exudates ( Dilated).

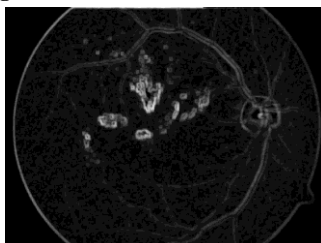


Fig 3 (b): Shows Exudates (Eroded).

#### 5. DETECTION OF MACULAR DEGENERATION FEATURES USING GABOR FILTER[7]

After reading the image, it is converted into gray scale. Then the maximum minus the minimum of pixels is calculated to find the edges. Then we use a line structuring element to dilate the image. Finally convolve the image with a 3\*3 matrix such that the gabor matrix matches[16] the frequencies of the image. If a bigger size matrix is used, diabetic features can be found out. The equations for Gabor filter are given as follows:

$$G(S_x, S_y, U, V) = \left( \frac{1}{2\pi S_x S_y} \right) * e^{-\frac{1}{2} \left( \frac{x}{S_x} \right)^2 + \left( \frac{y}{S_y} \right)^2 + 2\pi i (Ux + Vy)}$$

Eq- 4.

where  $U = 0.25 + 2i \frac{N_c}{4}$ ,  $V = 0.25 - 2i \frac{N_c}{4}$   
and  $i = 1, 2, \dots, \log N_c / 8$ ,  $N_c$  is width of the image.  
and  $S_x, S_y$  are standard deviations in x and y directions and U and V are frequencies among x and y directions. Results are shown in Fig 4. And  $x = x_1 \cos A + y_1 \sin A$  and  $y = x_2 \cos A + y_2 \sin A$ . Here A and the frequencies are the chosen parameters. The steps for Gabor filter are as follows:

- Read the image in gray scale.
- Convert the image to black and white by applying entropy thresholding.
- Find Maximum – Minimum[7] for each pixel.
- Find edge of the image using Sobel operator[7].
- Using structuring element as line, dilate the image.
- Convolve the image with a three by three matrix which is of arbitrary shape near the macula.
- Mark those points.

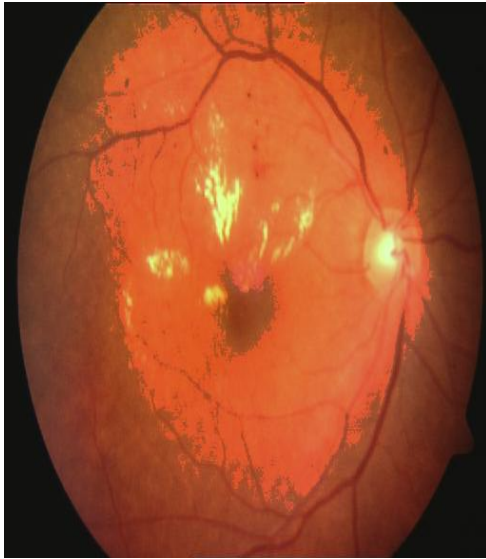

Fig 4:Shows extraction of Degenerated Macula using Gabor filter.

## 6. DETECTION OF BLOOD VESSELS USING RIDGE BASED SEGMENTATION

The ridge based segmentation technique uses the scaling factor and then the normalization[7] factor is defined using the scaling factor. Then the dominant angles are calculated to project the segmented image. The equations for scaling factor and normalization are as follows:

for x<-1 to 565

do for y<-1 to 565

do

$$\alpha(x, y) = \sqrt{(I_{xx}(x, y) - I_{yy}(x, y))^2 + 4(I_{xy}(x, y))^2}$$

(Eq-5)(Calculates Scaling Factor)

$$N(x, y) = \sqrt{((I_{yy}(x, y) - I_{xx}(x, y)) + (\alpha(x, y))^2 + 4(I_{xy}(x, y))^2}$$

(Eq-6)(Performs Normalisation)

end

end

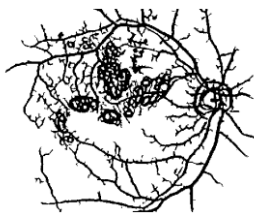

Fig 5 (a): Shows Macular Degeneration across white background.

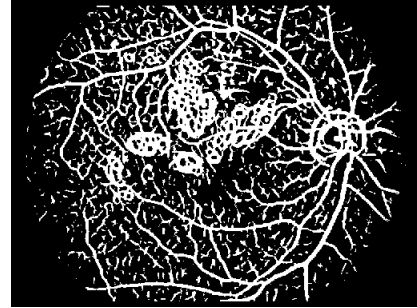


Fig 5 (b):Shows a fully segmented retinal image(Original image from Fig 1).

## 7. ANALYSIS

In this paper decision tree and k nearest neighbor methods have been used to classify the images into normal or abnormal retinal patterns based on artifacts and diseased features like the diabetic features. In the method of decision trees, the entropy is considered and when the features are non repeating in a group where the contribution of white pixels is same, misclassification happens. In case of k nearest neighbor, statistical significance is calculated, Euclidean distances amongst features is calculated, new statistical significance is calculated to prove, to which set the element belongs to. The percentage accuracies are given below in the table.

Non Diseased	Diseased
90% (Decision tree), 74%(KNN)	94%(Decision tree), 61%(KNN)

Fig 6:Shows table for classification accuracies.

From the table it is clear that when an artifact is found we get better results for classification using decision tree and KNN. When diseased features are present, chances for misclassification are more as artifacts and diseased features have the same shapes but not color parameters. So it is very apparent that when diseased features have to be classified, better methods have to be incorporated so that misclassification rates reduce. It has also been seen in this paper that the features selected are statistically significant. The method of segmentation doesn't take into account the color information of the images, where as if the red, green and blue component are taken into consideration, better results are obtained as the color information helps in extracting features like vessels or exudates in the case of diabetes. There are some interesting observations seen in this paper.

Section 2 shows extraction of features like vessels using LOG filter. Section 3 shows extraction of features like the bifurcation points using LOG filter. But LOG filter leaves a lot of blur in the images, so the resulting output is not clear. Section 4 shows extraction of vessels using morphology and we see the diseased features in the resulting output. Section 5 shows the extraction of bifurcation points using gabor filter. Section 6 shows the fully segmented image. In all these sections, a logical conclusion is made that the distance parameter using gabor filter has no effect to determine whether a feature is artifact or diseased. So if retinal patterns are considered as biometrics, only the artifacts or diseased feature can determine whether a retinal pattern is normal or abnormal. The following graph as shown in Fig 7 shows the images as diseased with the yellow curve, pink curve shows artifacts and blue curve shows the normal retinal patterns. On

the x axis are the images and on the y axis is the contribution in terms of number of white pixels in the artifacts and the diseased patterns.

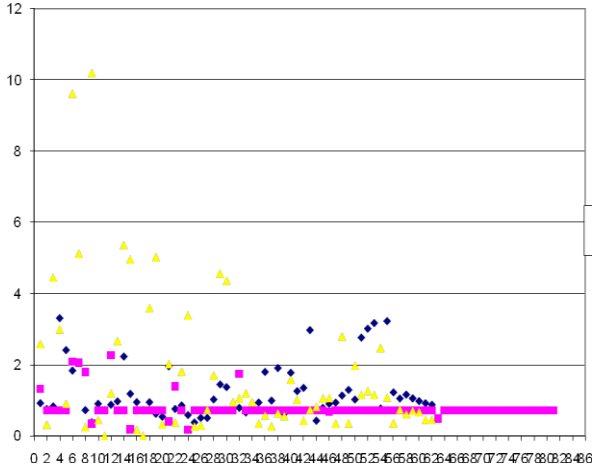


Fig 7: Graph with area and image indices.

## 8. DISCUSSION

In this paper an attempt has been made to calculate the areas occupied by the macula in Macular Degeneration. The total number of images considered are eighty one and the ratios of the areas of the retinal ball to the ratios of the macula are calculated and it has been seen that clinical diagnosis can be better done using these results.

## 9. CONCLUSION

In this paper segmentation of retinal images gives lot of insight into the extraction of artifacts and diseased features of retina specially the diabetic features and it has been seen through the classification methods that images with artifacts only gives good classification accuracy when compared with those with diseased features because artifacts and diseased features have different styles of extraction. Nevertheless using better image processing techniques we can classify different diseases like hypertension, glaucoma and many other retinal disorders. Like diabetic retinopathy in medical science there diabetic uropathy and diabetic neuropathy where in the kidneys and the nervous system gets affected. But in this paper the main concentration has been on general classification into normal and abnormal patterns. More work can be done in specific diseases where in clearly it can be understood what is the difference between artifact, micro-aneurysms, hemorrhages, exudates, where micro-aneurysms, hemorrhages, exudates are diabetic features. Like wise there are different sets of features for glaucoma, hypertension and other diseases.

## 10. References

[1] Subhasish, C., Shankar, C., Norman, K., et-al(1989). *Detection of Blood Vessels in Retinal Images using Two Dimensional Matched Filters*, IEEE Transactions on Medical Imaging, Vol.8, No 3, pp 34-45.  
 [2]. Luo ,G., Opas, C., Shankar, M. K.(2009). *Detection and Measurement of Retinal Vessels in Fundus Images using Amplitude Modified Second Order Gaussian Filter*, IEEE Transactions on Biomedical Engineering, Vol.49, No 2, pp23-32.  
 [3]. Axel, P., Stefan, B., Peter, D., et-al(1998). *Mapping the*

*Human Retina*, IEEE, Transactions on Medical Imaging, Vol.17, No 4, pp 45-56.  
 [4]. Fredric, Z., Jean, C. K.(2009). *Segmentation of Vessel like Patterns using Mathematical Morphology and Curvature Evaluation*, IEEE Transactions on Image Processing, Vol.10, No 7, pp 56-67.  
 [5]. Stiliyan, N. K., Joes, S., Bart, M., et-al.(2001). *A Computational Method for Segmenting Topological Point - Sets and Application to Image Analysis*, IEEE Transactions on Pattern Analysis and Machine Intelligence, Vol.23, No 5, pp 34-42.  
 [6]. Xiaoi, J., Daniel, M. (2009). *Adaptive Local Thresholding by Verification based Multi Threshold Probing with application to Vessel Detection in Retinal Images*, IEEE Transactions on Pattern Analysis and Machine Intelligence, Vol.25, No 1, pp 23-30.  
 [7]. Joes, S., Michael, D. A., et-al.(2004). *Ridge based Vessel Segmentation Color Images of the Retina*, IEEE Transactions on Medical Imaging, Vol.23, No 4, pp 23-29.  
 [8]. Jayadevan, R, Jayant, V K., et-al.(2006). *A New Ridge Orientation based Method of Computation for Feature Extraction from Fingerprint Images*, Journal of Medical Imaging, World Academy of Science, Engineering and Technology, Vol 22, No 3, pp 45-56.  
 [9]. Vratislav, H., et-al.(2003). *Automated Landmarks Detection for Retinal Image Registration*, Doctoral Thesis, Supervisor Radim Kolar.  
 [10]. Zakaria, B. S., Laurent, D. C., Gérard, M., and Gabriel, C.(2010). *A New Approach of Geodesic Reconstruction for Drusen Segmentation in Eye Fundus Images*, IEEE Transactions on Medical Imaging, Vol 20, No.12, pp 34-45.  
 [11] Oliver, F , Acharya, U. R. , Ng, E.Y.K. , Ng, K.H. ,Jasjit, S. S.(2010). *Algorithms for the Automated Detection of Diabetic Retinopathy Using Digital Fundus Images: A Review*,Journal of Medical Systems, Vol 23, No 5, pp 23-34.  
 [12] Qin, L, Jane, Y, Lei, Z, Prabir, B(2008). *Automated Retinal Vessel Segmentation Using Multiscale Analysis and Adaptive Thresholding*,Proceedings of IEEE Conference.  
 [13] Harihar, N., James, M. B., Bahram, K., Badrinath, R.(2010). *Automatic Identification of Retinal Arteries and Veins From Dual-Wavelength Images Using Structural and Functional Features*,IEEE Transactions on Information Technology and Biomedicine, Vol 54, No 8, pp 1427-1435.  
 [14] Carmen, A. L. , Domenico, T., Emanuele, T.(2010). *Retinal Vessel Segmentation Using AdaBoost*,IEEE Transaction on Information Technology and Biomedicine, Vol 14, No 5 ,pp 1267-1274.  
 [15] Harihar, N., Vijay, M., James, M. B., and Badrinath, R.(2011). *Improved Detection of the Central Reflex in Retinal Vessels using a Generalized Dual-Gaussian Model and Robust Hypothesis Testing*,IEEE Transaction on Information Science , Vol 12, No 3, pp 405-410.  
 [16] Aliaa, A.A.Y., Atef, Z. G., Amr, A. S. Abdel, R. G.(2010). *Optic Disc Detection From Normalized Digital Fundus Images by Means of a VesselsDirection Matched Filter*, IEEE Transaction on Information Technology and Biomedicine.