

# Segmentation of Preprocessed MR and CT Images Containing Tumors using Edge Detection and Watershed Segmentation

Sonali Patil

Ph.D. Scholar, Shivaji University, Kolhapur,  
Associate Professor, Department of IT,  
KJSCE, Mumbai, India

V. R. Udipi, Ph.D

Professor, Department Of Electronics and  
Communication Engineering, GIT,  
Belgaum- 590 008, India

## ABSTRACT

Segmentation of images aims at dividing areas corresponding to different objects. There are two approaches for image segmentation, one is based on discontinuities and other is based on similarities. These approaches can be used for enhancing and extracting the tumor area in MRI/CT images. In this paper Sobel and Extended Sobel edge operators are applied on the MRI / CT images containing tumors. It is noticed that the MR/CT images contain unwanted portions that make segmentation difficult. If such images are segmented without any preprocessing for removal of the unwanted portions, it results into over segmentation. In this paper, we propose to use Preprocessed MRI/CT image for the segmentation by using Sobel and extended Sobel operators. Results of both the methods on original and preprocessed images are displayed. The results of Watershed segmentation algorithm on original and preprocessed images are also displayed. It is observed that, the appropriate preprocessing of MR/CT images helps to significantly reduce the problem of over segmentation of these images still retaining the tumors.

**Keywords**—MRI, CT, Preprocessing, Segmentation, edge operator, extended edge operator, watershed

## 1. INTRODUCTION

Medical image processing is used as an important tool in computer-aided diagnosis for assisting doctors in evaluating medical imagery or in recognizing abnormal findings in a medical image. Structures of interest include organs or parts thereof, such as cardiac ventricles or kidneys, abnormalities such as tumors and cysts, as well as other structures such as bones, vessels, brain structures etc.

Magnetic Resonance Imaging (MRI) and Computed Tomography Ehsan Nadernejad [1] compared several techniques for edge detection in image processing. From the three methods of edge detection, Robert, Prewitt, and Sobel, Sobel method is more suitable for edge detection of tumor because it has a little mean and standard deviation value. Sobel operator gives good performance image, with edge line between other tissues and tumor tissues sharper than other methods of edge detection [2-3]. Dr. H. B. Kekre et al. [4] have proposed extended edge operator for segmentation of mammographic images. Basim Alhadidi [5] compared Thresholding, Edge based and Watershed Segmentation with respect to the execution time. D. Brzakovic et al. [6] used thresholding and fuzzy pyramid linking for mass localization and classification. Mudigonda et al. [7] detected an area of major

CT are vital diagnostic imaging techniques. MRI scan uses magnetic fields to generate pictures of inside of the body as compared to the X-ray beams used in CT scans. Advantage of MRI is that the soft tissue contrast is much better than with X-rays leading to higher-quality images, especially in brain and spinal cord scans. Also, MRI technique utilizes strong magnetic fields and non-ionizing radiation in the radio frequency range, and according to current medical knowledge, is harmless to patients. But, MRI scans are used only in a few situations, like diagnosing brain tumors and primary bone tumors. CT scans, on the other hand, still remains one of the best medical tests and tools for early detection of various diseases. A CT image can be obtained within one breath hold which makes CT the modality of choice for imaging the thoracic cage.

During a MRI/ CT scan, the patient may be advised to take a contrast (dye) so that resultant images of a specific part of the body have greater clarity. This may be essential to detect the presence of a foreign object, or to diagnose any minute defects in a specific organ. When the image of a specific body part is produced using a contrast agent, certain areas of the image are highlighted. In other words, a precise visualization of the specific area of the organ is achieved, which in turn helps to assess complications in the organ.

Medical image segmentation refers to the segmentation of known anatomic structures from medical images. Medical image segmentation is often application-specific. This has led to the development of a wide range of segmentation methods addressing specific problems in medical applications. The choice of segmentation algorithms vary between manual, semiautomatic or fully automatic methods. The segmentation process is usually based on gray level intensity, texture, color or shape.

## 2. RELATED WORK

directivity by calculating correlation between gradients and pixel values belonged to a fixed-size window. H B Kekre et al. [8] proposed various segmentation techniques based on statistically measurable features in image. A fast and flexible algorithm for computing watersheds in digital gray-scale images was introduced by L Vincent et al. [9]. Matei Mancas et al [10] dealt with a novel semi-automatic segmentation method giving realistic results on head and neck tumors. Saif D. Salman et al. [11] used watershed method and image processing to detect the tumor boundaries in MRI and CT image for different cases. Meyer et al. [12] used topographic distance for watershed segmentation. Thor Ole Gulsrud et al. [13] used Watershed segmentation on detected masses in digital mammograms. But the segmentation methods

based on watershed transform method results into over segmentation. M. Frucci et al. [14] addressed this problem of over segmentation to some extent. But the medical images have different data like film artifacts and labels which also led to over segmentation if not removed. So the preprocessing is required on MRI/CT images to remove these unwanted portions like film artifacts, etc and also to remove the noise. It is also sometimes necessary to remove the effect of skull portions in Brain MR images. Inappropriate preprocessing or no preprocessing leads to improper and over segmentation. Tracking algorithms were proposed by Jaya et al. [17] for preprocessing. But these tracking algorithms use highest threshold for gray scale image which is 255. This removes artifacts which have a gray value of 255 only leaving all other artifacts on the image. This algorithm also removes data from tumors. The tracking algorithm used for removal of skull portions in the brain MR image uses threshold [200 -255] to remove skull portions. This will additionally remove required data form ROI located adjacent to skull.

We propose median filtering and Morphological Erosion for preprocessing of MR and CT images. The work done is to segment the MRI images of brain using Sobel edge operators [3], extended edge operators [4] and watershed algorithm [12] after preprocessing the images. Results of segmentation of original and preprocessed images containing tumors are displayed for comparison. The aim of the proposed algorithm is to retain the tumors in the MR/CT images enhancing the boundary between the tumor tissues and other tissues and also to minimize the detection of other edges which are not relevant to the tumors in the image.

### 3. PROPOSED ALGORITHM

- Step1. Load the image
- Step2. Apply the median filtering.
- Step3. Use Morphological Erosion with square shaped structuring element. Apply erosion using Structuring Element three times but every time change the size of structuring element (1st time by size 4 \* 4, 2nd time by size 3\*3 and 3rd time by size 2\*2)
- Step5. Apply edge detection operators/ watershed transform for segmentation.

Here the median filtering removes all the film artifacts and removes salt and pepper noise. The erosion operation, as stated in the above manner, reduces the effect of skull portions/ribcage portions in Brain/Abdomen MRI/CT images.

### 4. RESULTS

The algorithms were applied on 25 different MRI/CT scans of Brain, Thorax and Abdomen containing tumors. The methods used for segmentation were Sobel edge operator, Extended Sobel operator and watershed segmentation on original and preprocessed images. The results are displayed in fig.1 to fig.5 for five different MRI/CT images of Brain, Abdomen and Thorax.

In each of this figure: a is original image, b is edge detection using Sobel Operator on Original Image, c is edge detection using Extended Sobel Operator on Original Image, d is Watershed segmentation on Original Image, e is Preprocessed image, b is edge detection using Sobel Operator on Preprocessed Image, c is edge detection using Extended Sobel Operator on Preprocessed Image, d is Watershed segmentation on Preprocessed Image.

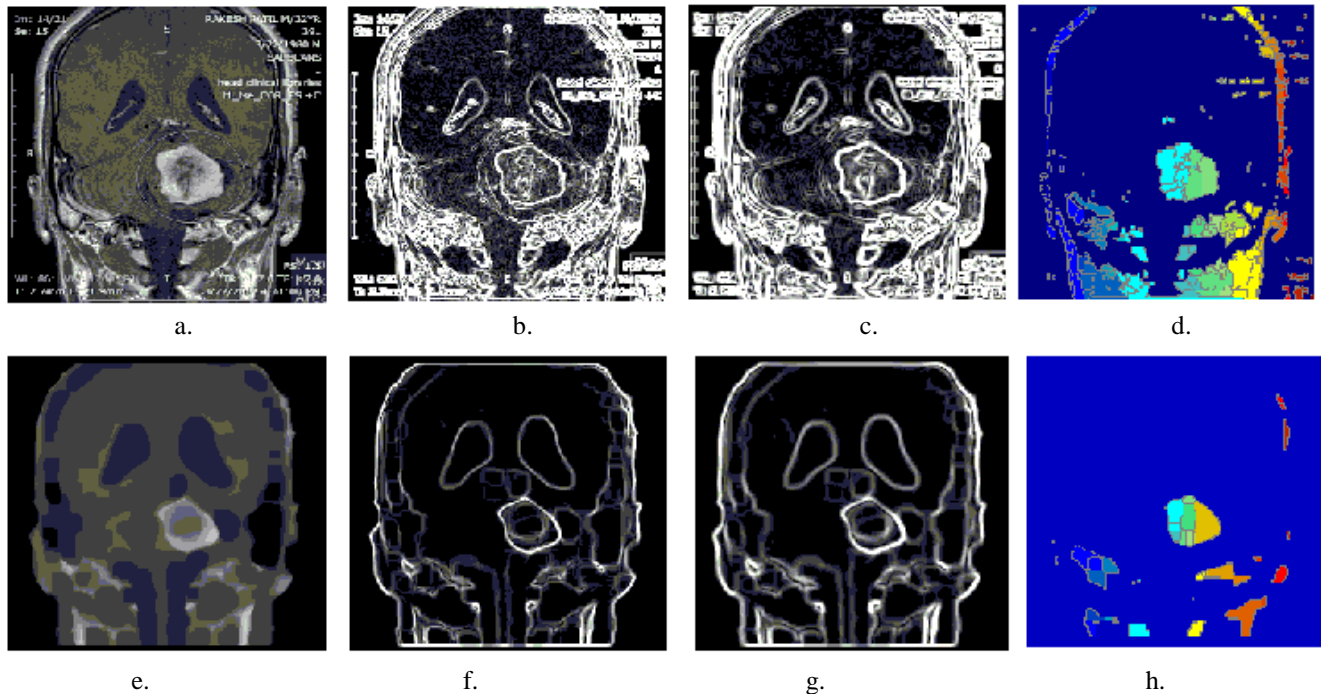
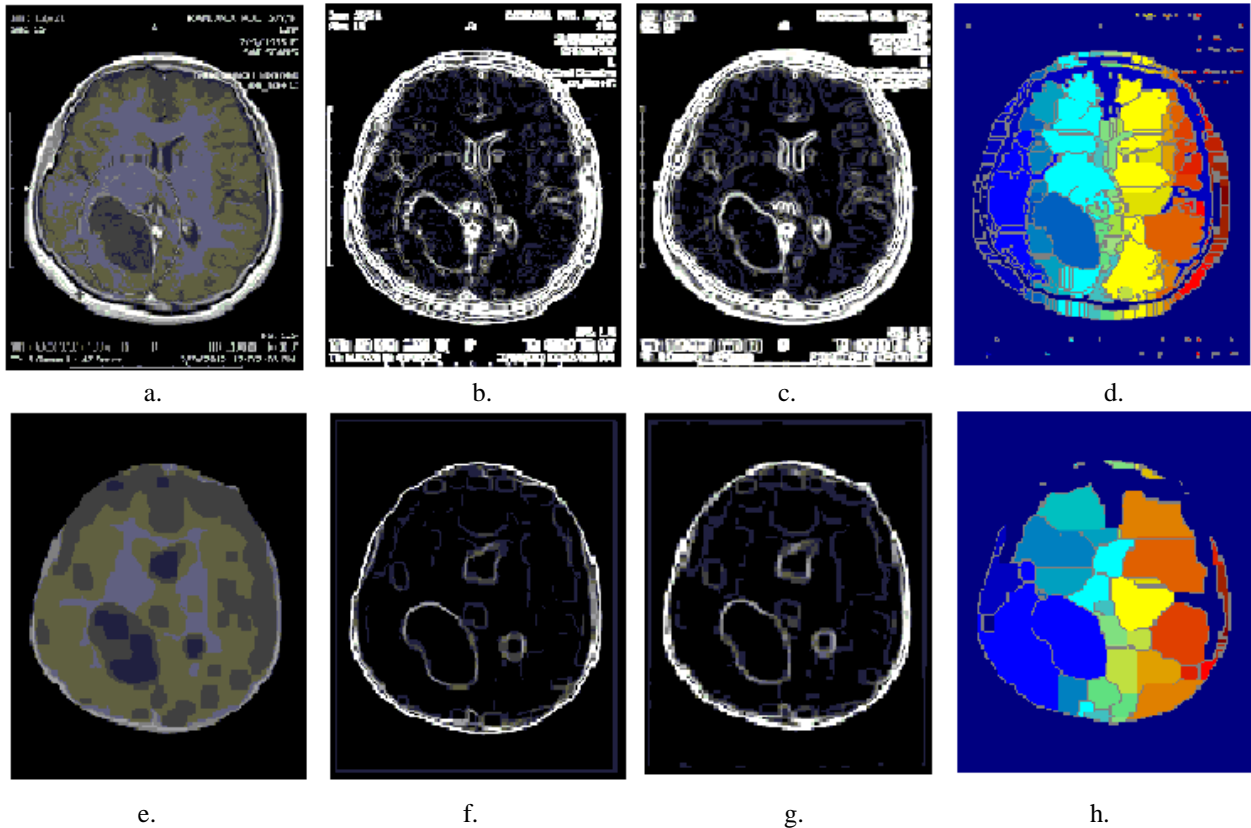
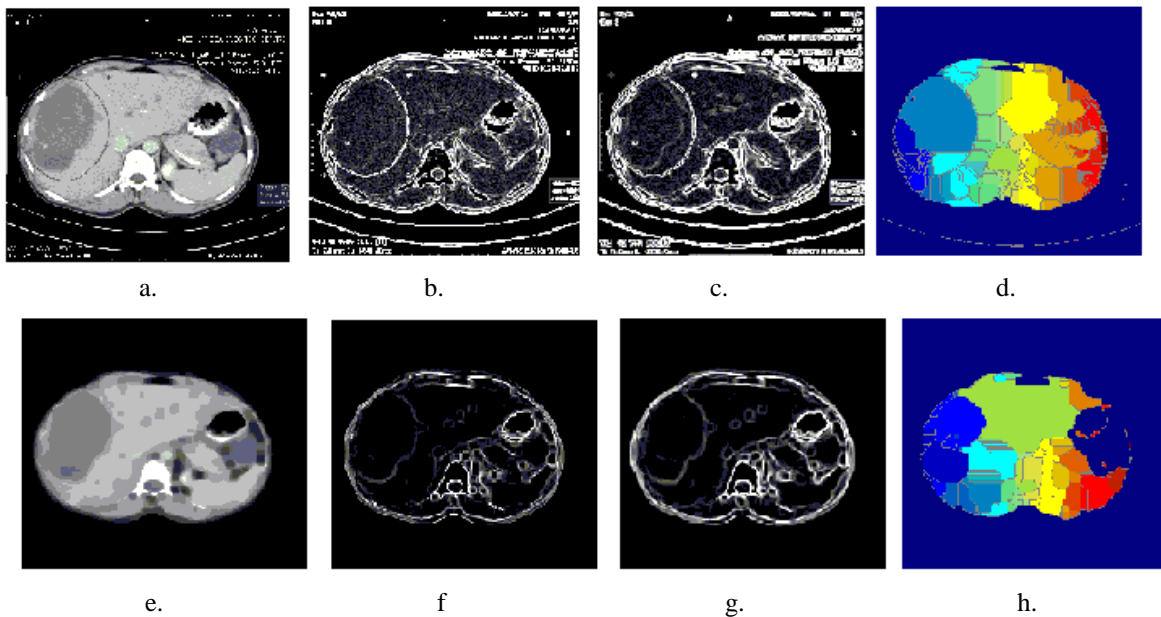


Fig 1. Results on coronal view of a T1W Brain MR Image with contrast containing Tumor



**Fig.2 Results on transverse sections of a T1W Brain MR Image with contrast containing Tumor**



**Fig.3 Results on CT image of Abdomen containing Liver Tumor**

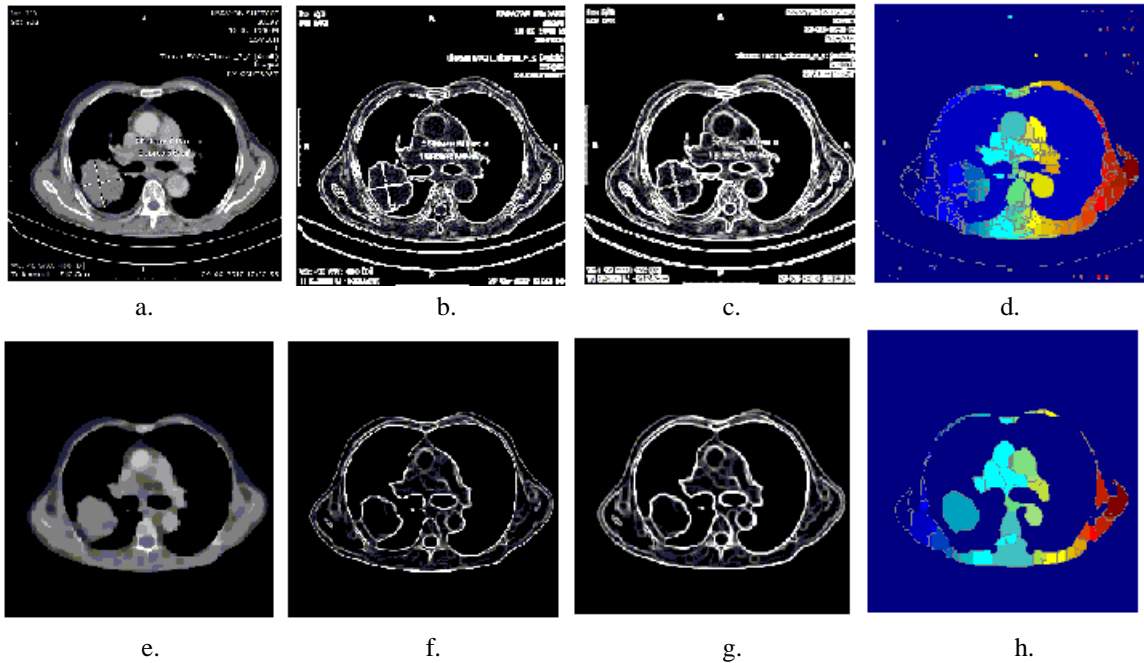


Fig.4 Results on CT image of Thorax with contrast containing Lung Tumor

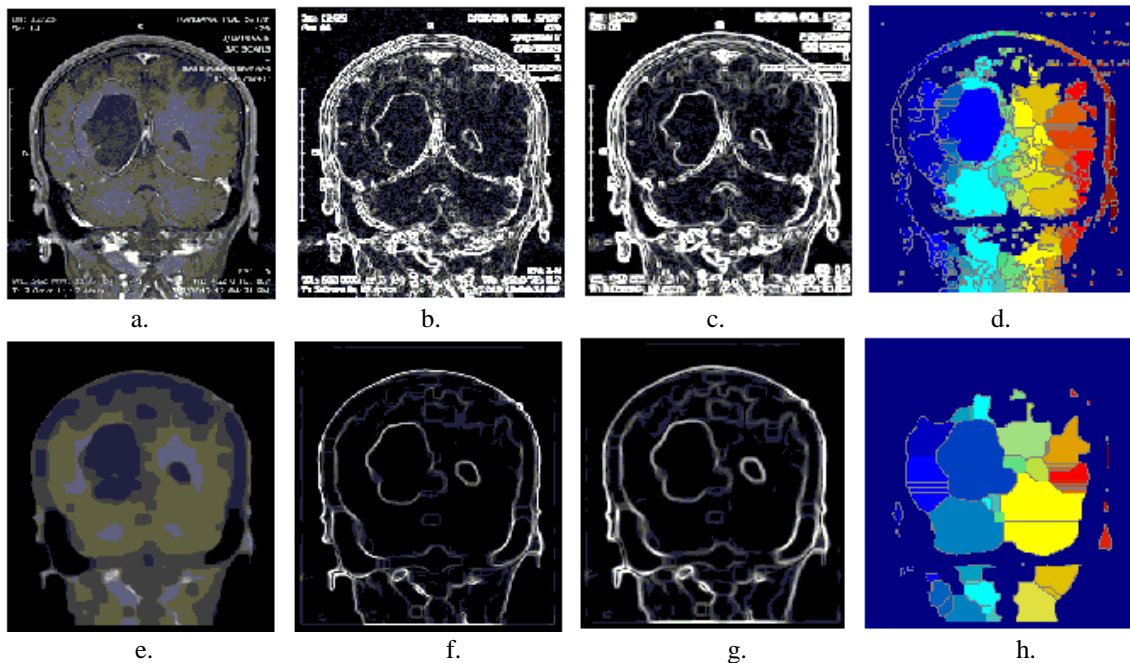


Fig.5 Results on MR image of Brain with contrast containing Tumor

## 5. CONCLUSIONS

From the displayed results it is seen that edge detection on original image leads to detection of edges which are not of relevance from the point of enhancement of tumor. In this case the tumor may or may not be retained as seen from images b and c of fig.3. The edge detection operators give far better results in terms of segmentation and retention of tumors. The watershed segmentation is known to produce over segmentation. But, if watershed segmentation is carried on preprocessed image, as proposed, the over segmentation

problem significantly subsides. It is also seen that the Extended Edge operator gives better results considering prominent edges.

## 6. ACKNOWLEDGMENT

We would like to thank management of Siddhivinayak Cancer Hospital and Akshay Diagnostic Centre for providing us the MR and CT images.

## 7. REFERENCES

- [1] Ehsan Nadernejad," Edge Detection Techniques: Evaluations and comparisons", *Applied Mathematical Sciences*, Vol. 2, no. 31, pp. 1507 - 1520, 2008.
- [2] Riries Rulaningtyas and Khusnul Ain, "Edge Detection for Brain Tumor Pattern Recognition", <http://ieeexplore.ieee.org/stamp/stamp.jsp?arnumber=05417299>
- [3] Gonzalez, R.C. and R.E. Woods, *Digital image processing*, Pearson Education, 2002.
- [4] Dr. H. B. Kekre and Ms. Saylee M. Gharge, "Image Segmentation using Extended Edge Operator for Mammographic Images", *International Journal on Computer Science and Engineering*, Vol. 02, No. 04, pp.1086-1091, 2010.
- [5] Basim Alhadidi, Mohammad H., " Mammogram Breast Cancer Edge Detection Using Image Processing Function", *Information Technology Journal* 6(2):217-221,2007, ISSN-1812-5638
- [6] D. Brzakovic, X. M. Luo, and P. IBzakovic, "An approach to automated detection of tumors in mammography," *IEEE Trans. Med. Imag.*, Vol. 9, no. 3, pp. 233-241, Sept. 1990.
- [7] Naga R. Mudigonda, Rangaraj M. Rangayyan and J. E. Leo Desautels, "Detection of Breast Masses in mammograms by Density Slicing and Texture Flow-Field Analysis", *IEEE RANSACTIONS ON MEDICAL IMAGING*, VOL. 20, NO.12, pp. 1215, DECEMBER 2001
- [8] Dr. H. B. Kekre, Ms. Tanuja K. Sarode and Ms. Saylee M. Gharge, "Detection and Demarcation of Tumor using Vector Quantization in MRI images", *International Journal of Engineering Science and Technology*, Vol.1(2), pp.59-66, 2009.
- [9] L. Vincent, P. Soille, "Watersheds in digital spaces: An efficient algorithm based on immersion Simulations" , *IEEE Trans. PAMI.*, 13 (6),pp. 583-593, 1991.
- [10] M. Mancas and B. Gosselin, Fuzzy Tumor Segmentation based on Iterative Watersheds, *Proc. STW Conf. of ProRISC*, Veldhoven, Netherlands, 2003.
- [11] Saif D. Salman & Ahmed A. Bahrani, "Segmentation of tumor tissue in gray medical images using watershed transformation method", *International Journal of Advancements in Computing Technology*, Volume 2, Number 4, October 2010.
- [12] Meyer, Fernand, "Topographic distance and watershed lines," *Signal Processing* , Vol. 38, July 1994, pp.113-125.
- [13] Thor Ole Gulsrud, Kjersti Engan and Thomas Hanstveit, "Watershed segmentation of detected masses in digital mammograms", *Proceedings of the 2005 IEEE Engineering in Medicine and Biology*, 27th Annual Conference Shanghai, China, September 1-4, 2005
- [14] M. Frucci, Oversegmentation reduction by flooding regions and digging watershed lines, *International Journal of Pattern Recognition and Artificial Intelligence*, 20 (2006) 15-38.
- [15] Jaya , K.Thanushkodi , M.Karnan, Tracking Algorithm for De-Noising of MR Brain Images, *International Journal of Computer Science and Network Security*, 9(11), November 2009, 262-267